

Comprehensive Report

Example 1

Case Information

Study Details

CBCT, less than one whole jaw

Scan Date

1/27/2025

Image quality

Optimal for diagnosis

Clinical Indication

General review.

Radiographic Findings

Tooth #2:

A corticated, spherical radiolucency is present immediately distal to the root apices of tooth #2 and inferior to the floor of the maxillary sinus. This radiolucency appears distinct and unrelated to tooth #2, as the PDL space and lamina dura of #2 can be clearly traced and are within normal limits. Additionally, the adjacent floor of the maxillary sinus is intact and demonstrates no continuity with the radiolucency.

The radiographic appearance is most suggestive of an odontogenic cyst or neoplasm, such as an odontogenic keratocyst.

Tooth #3:

Tooth #3 demonstrates bone loss centered around the MB, DB, and P root apices. The areas of bone loss are continuous with the adjacent PDL space, which is also widened. These findings are consistent with apical periodontitis associated with tooth #3.

Three canals are visualized – MB, DB and P. No distinct or separate MB2 canal is identified within the MB root.

Dentition, Maxilla:

The remaining dentition and paradental bone appear unremarkable with no sign of infection or pathosis.

Other:

There is mild mucosal thickening along the floor of the right maxillary sinus.

The remaining bones, soft tissues, and other structures captured in the scan have been evaluated and appear within normal limits.

Radiodontics

The Premier Dental Radiology Experience

Impressions

Tooth #2:

A corticated radiolucency distal to the root apices of #2. **Radiographic findings are most suggestive of an odontogenic cyst or neoplasm, such as an odontogenic keratocyst. Biopsy is recommended for a definitive diagnosis.**

Tooth #3:

Apical bone loss, consistent with apical periodontitis. Correlation with patient symptoms and clinical findings is recommended.



Barrett Andreasen, DDS
Oral and Maxillofacial Radiologist

N/A

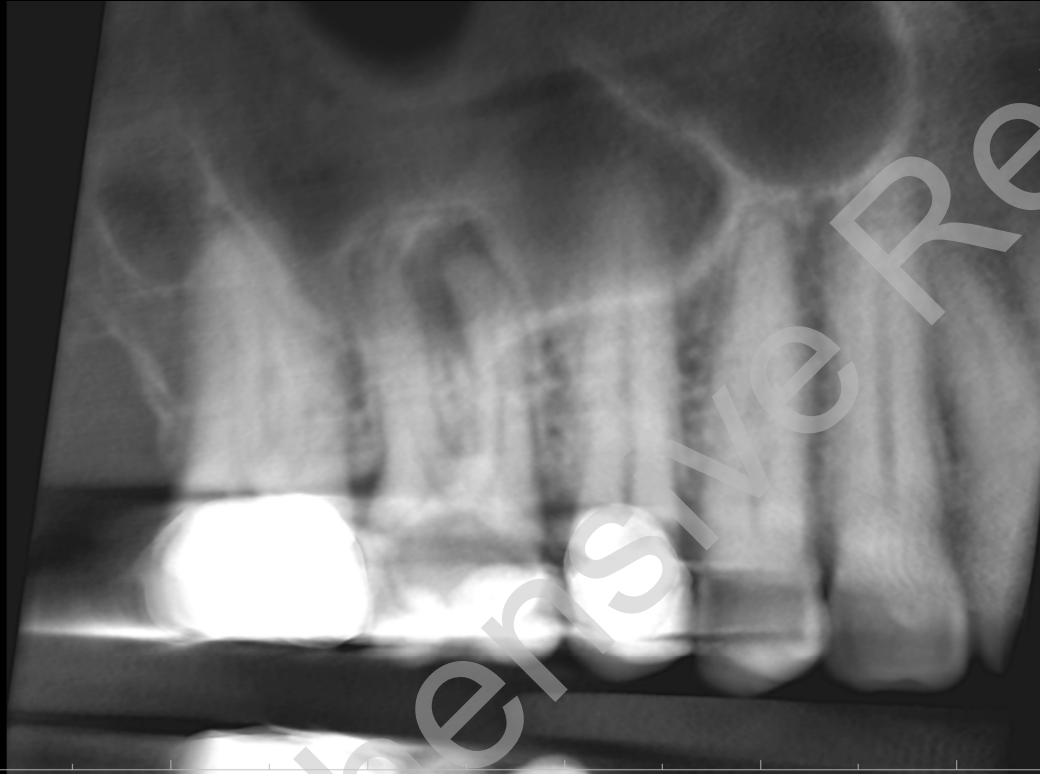Comprehensive Patient
N/A

1/27/2025

20
(mm)

0

Upper-Lower Limit

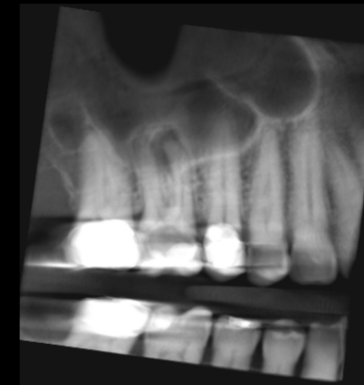
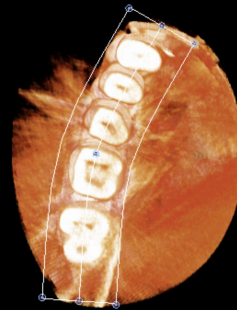
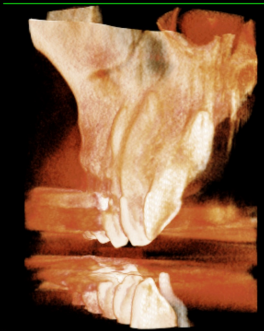

Focal Trough

Preview

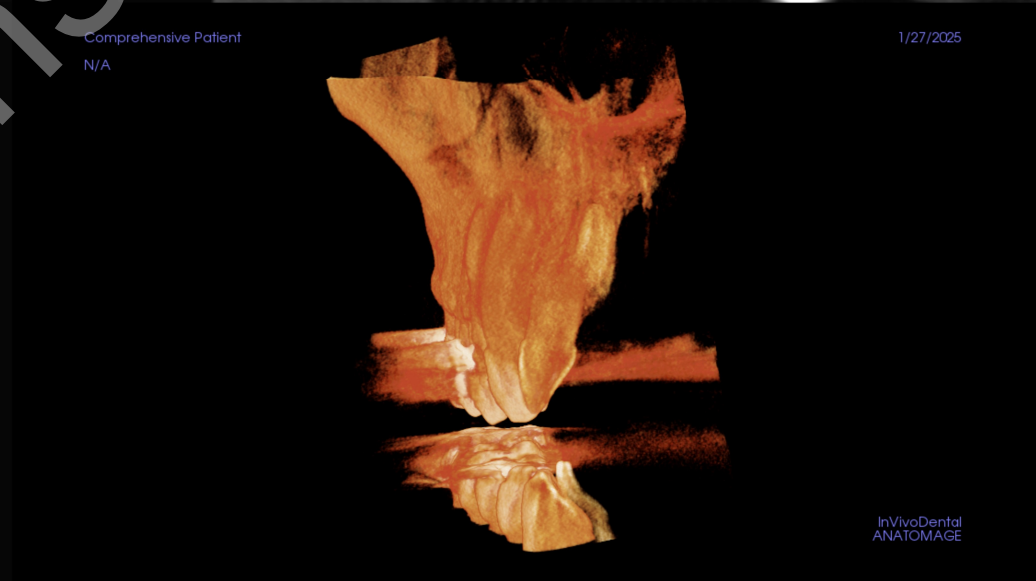
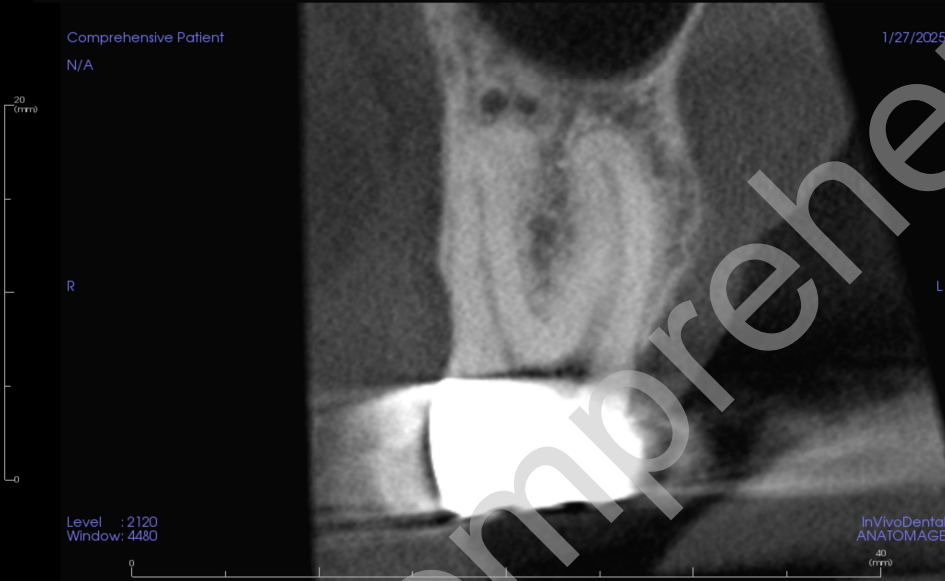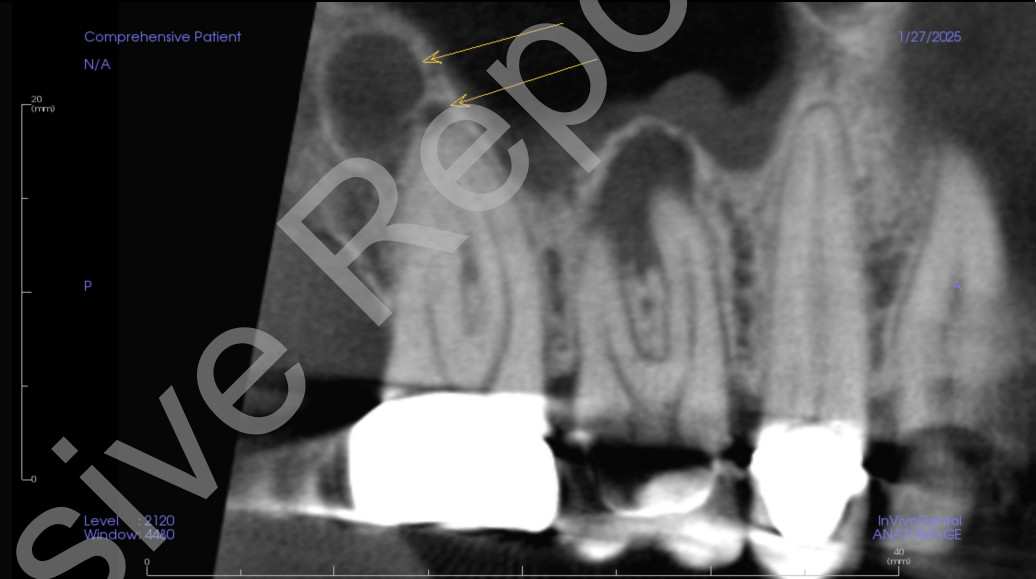
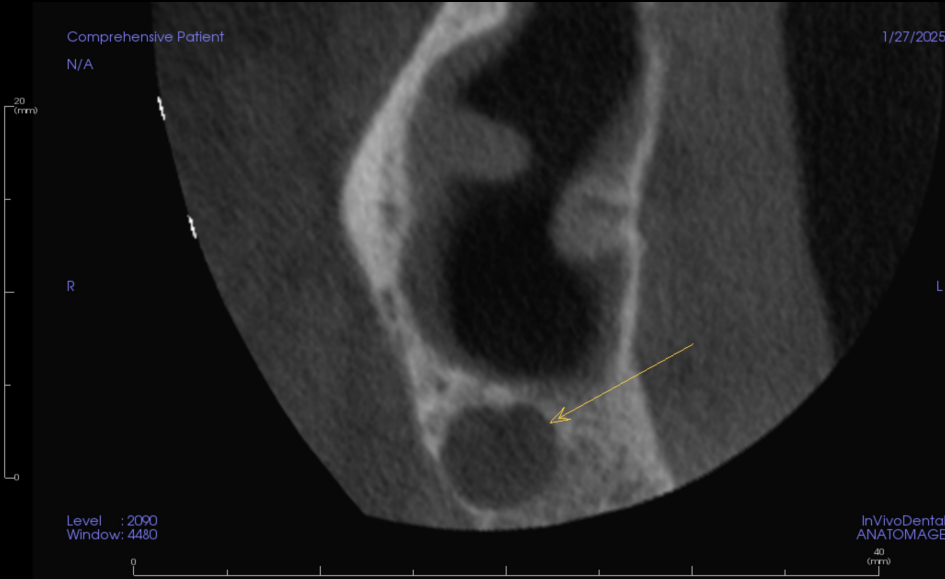
InVivoDental
ANATOMAGE

100
(mm)



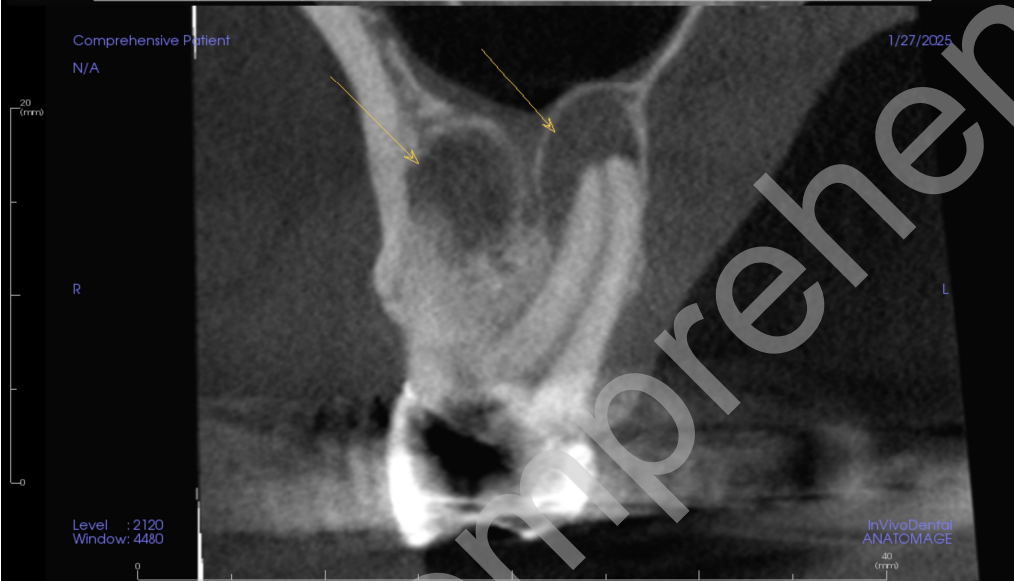
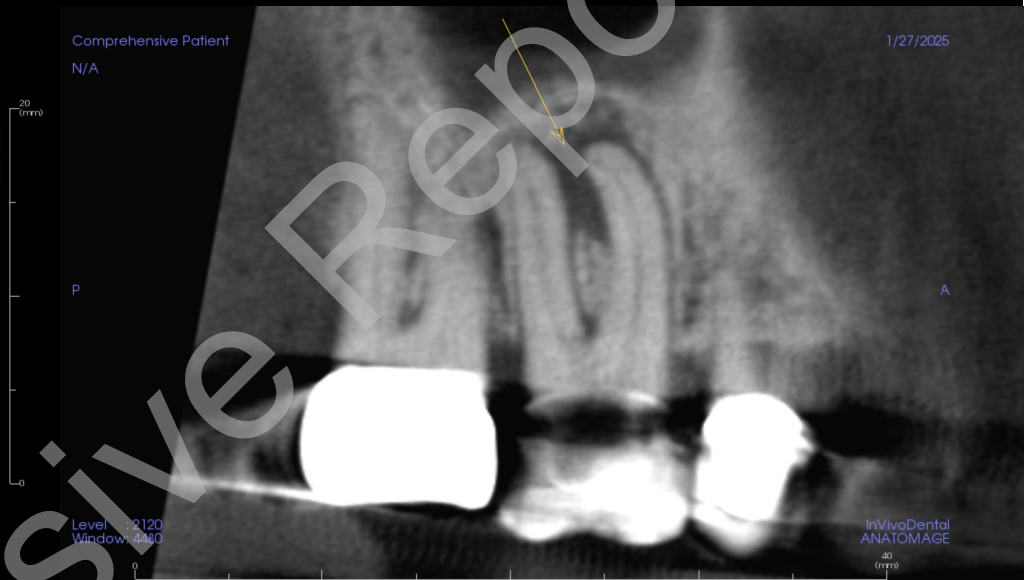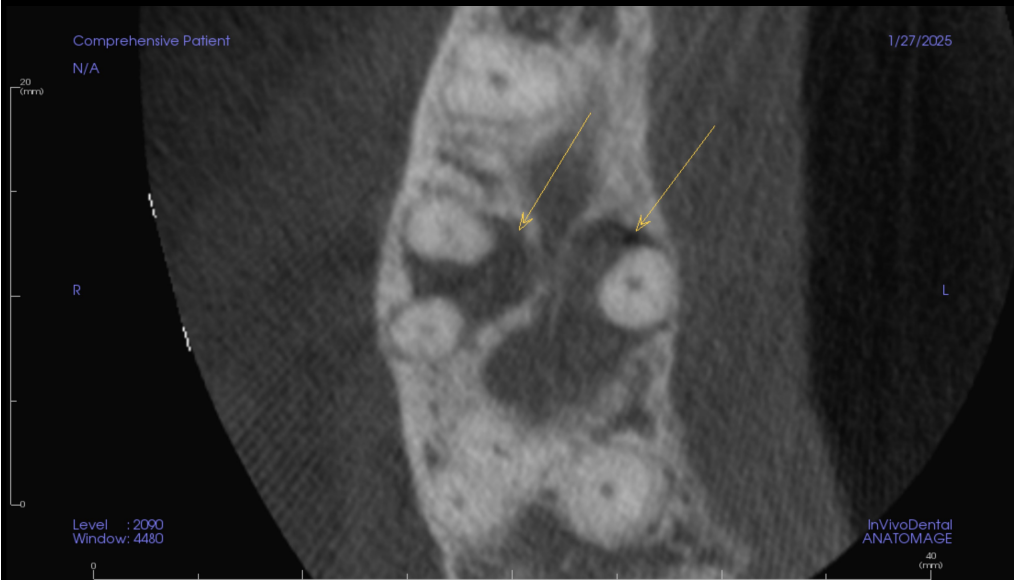
May Not Be Life Size

N/A



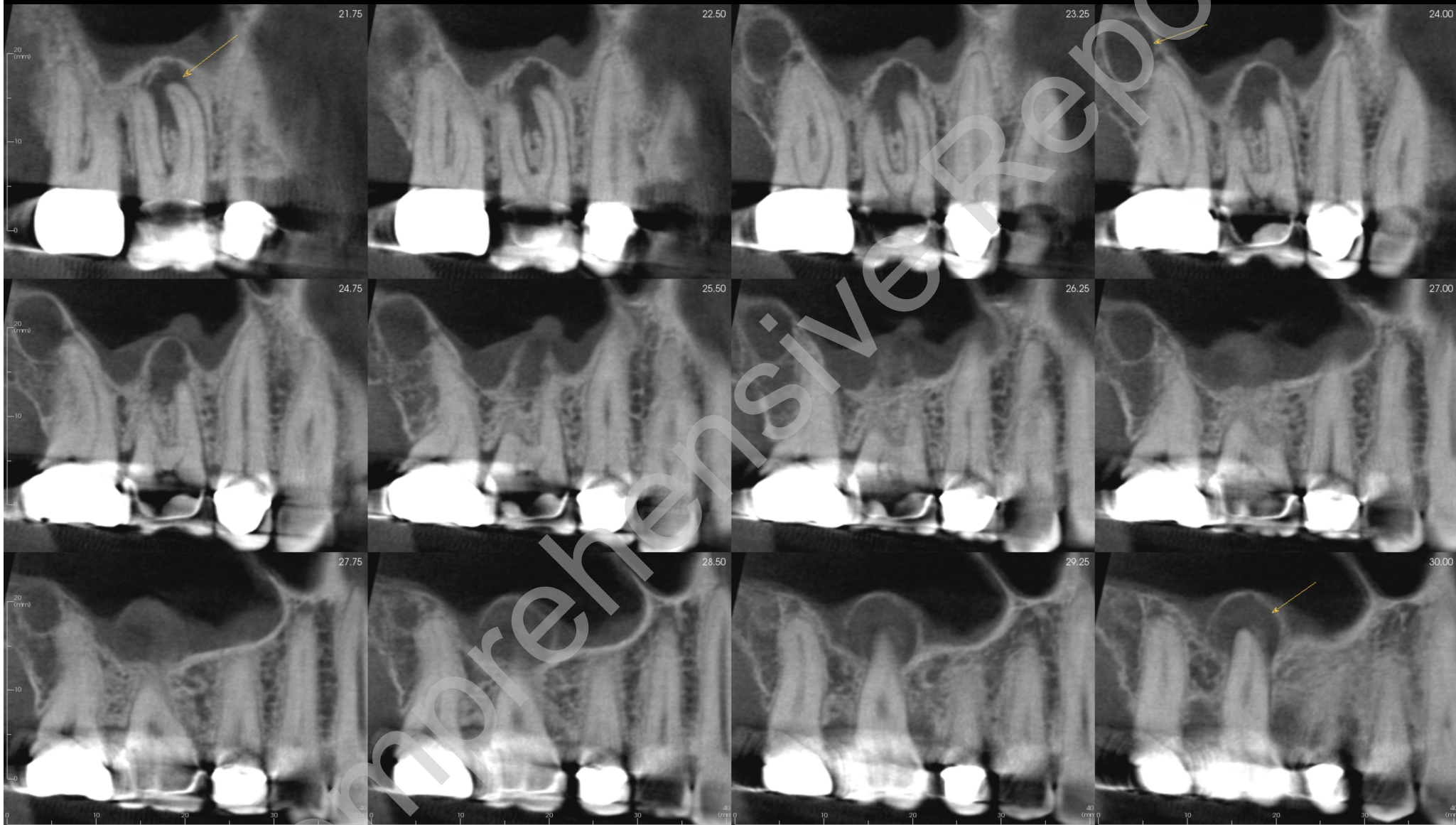
May Not Be Life Size

N/A



May Not Be Life Size

N/A



Pathology Screening

Example 1

Patient:

Date of Birth:

Referred By:

Case Information

Study Details

CBCT, less than one whole jaw

Scan Date

1/27/2025

Image quality

Optimal for diagnosis

Clinical Indication

General review.

Radiographic Findings

Dentition, Maxilla:

A corticated radiolucency distal to the root apices of tooth #2, most suggestive of a benign cyst or neoplasm, such as an odontogenic cyst.

Apical bone loss associated with #2, consistent with apical periodontitis.

The remaining dentition and parodontal bone appear unremarkable with no sign of infection or pathosis.

Other:

The remaining bones, soft tissues, and other structures captured in the scan have been evaluated and appear within normal limits.

Impressions

Dentition, Maxilla:

Radiolucency distal to the root apices of #2: **Radiographic findings are most suggestive of an odontogenic cyst or neoplasm, such as an odontogenic keratocyst. Biopsy is recommended for a definitive diagnosis.**

Tooth #3: Apical periodontitis



Barrett Andreasen, DDS
Oral and Maxillofacial Radiologist

Comprehensive Report

Example 2

Patient:

Date of Birth:

Referred By:

Case Information

Study Details

CBCT, both jaws with cranium

Scan Date

Image quality

Optimal for diagnosis

Clinical Indication

General review. TMJ and airway evaluation.

Radiographic Findings

Mixed density lesion, right maxilla:

Area mixed density, radiopaque/radiolucent lesion is seen within the lateral anterior portion of the right maxilla, involving the sinus walls and the alveolar ridge, extending from teeth #2 – 6. The lesion also spans to the floor the orbit, which does not appear displaced. Significant expansion of the cortices is noted, though no significant tooth displacement is seen. Of note, no extension of the lesion beyond the zygomaticomaxillary suture is noted.

The radiographic appearance is consistent with fibrous dysplasia.

Dentition, Mandible, Maxilla:

Teeth #17 and 32 are missing.

The dentition and remaining paradental bone appear unremarkable with no sign of infection or pathosis.

TMJs:

The left condylar head demonstrates a depression within the superior central surface. The appearance is most suggestive of a bifid morphology, a normal anatomical variation. Otherwise, the condylar heads demonstrate flattening of the articular surface with cortical thickening and trabecular sclerosis involving the right condylar head, suggestive of bone remodeling of the left and right TMJs.

Sinuses, Nasal Cavity, Airway:

The visualized sinuses are clear and well aerated.

There is leftward deviation of the nasal septum. Otherwise, the nasal structures are unremarkable.

The airway is patent with relatively symmetric soft tissue contours and demonstrates a minimum cross-sectional area of approximately 124.1mm², which is considered to be within normal limits (normal >110mm²).

Other:

The visualized portion of the cervical spine is within normal limits.

The remaining bones, soft tissues, and other structures captured in the scan have been evaluated and appear within normal limits.

Radiodontics

The Premier Dental Radiology Experience

Impressions

Mixed density lesion, right maxilla:

A mixed density lesion within the lateral anterior portion of the maxilla, consistent with fibrous dysplasia. This entity represents a benign fibro-osseous condition in which normal bone is replaced by abnormal fibrous tissue and immature bone. This entity is typically slow growing with growth often stabilizing or arresting after adolescence. Management is generally conservative, with clinical and radiographic follow-up recommended to monitor for any progressive growth. Surgical intervention is typically only considered when there is functional impairment, cosmetic concerns, or significant progressive growth. Biopsy is only indicated when significant growth is exhibited.

TMJs:

A bifid morphology involving the left condylar head (a normal anatomical variation).

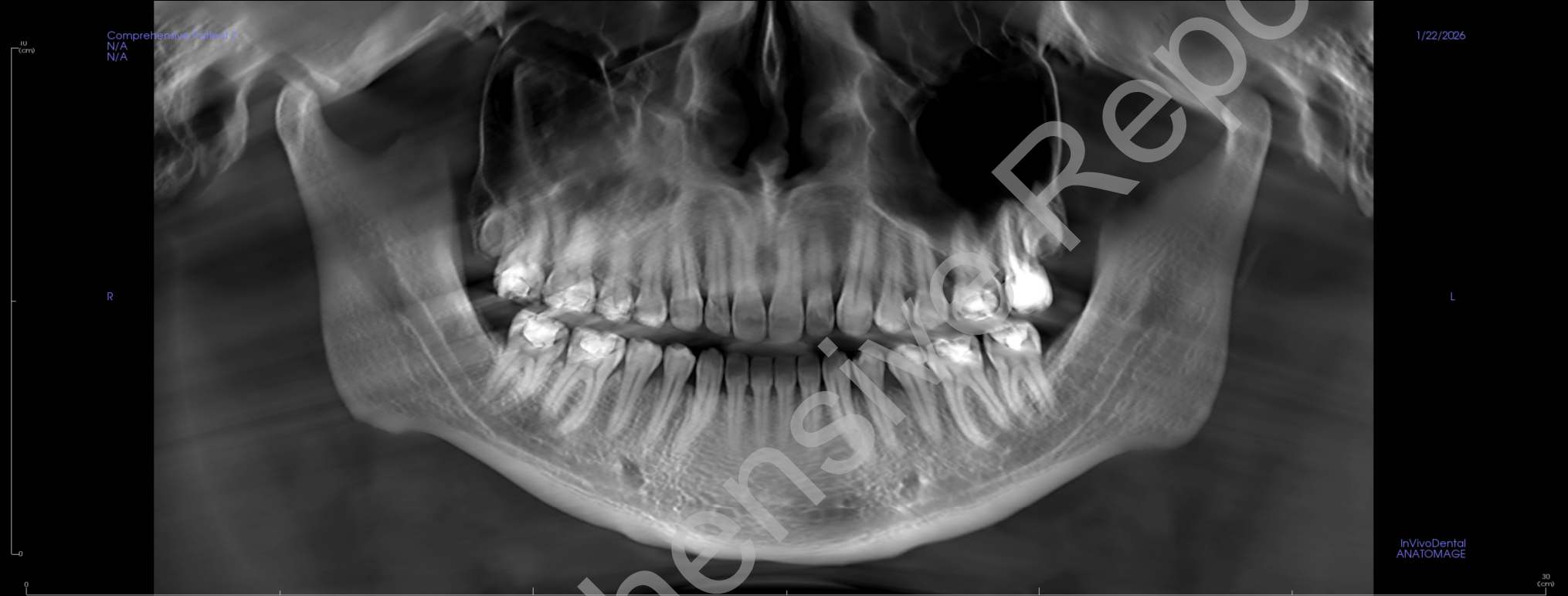Remodeling of the right and left TMJs, these changes are likely adaptive to altered or increased joint forces.



Barrett Andreasen, DDS
Oral and Maxillofacial Radiologist

N/A

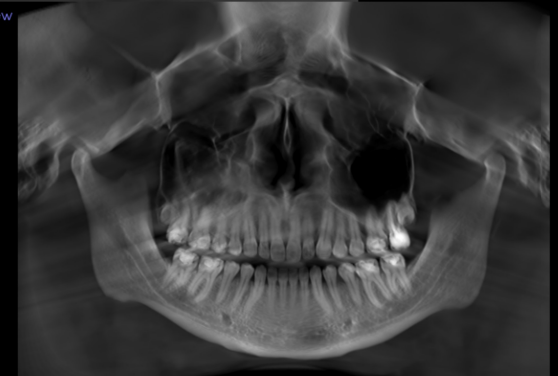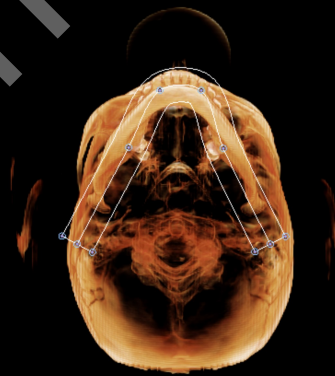
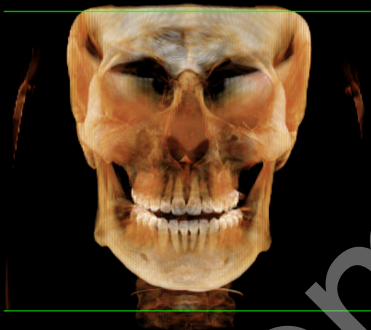N/A



Upper-Lower Limit

Focal Trough

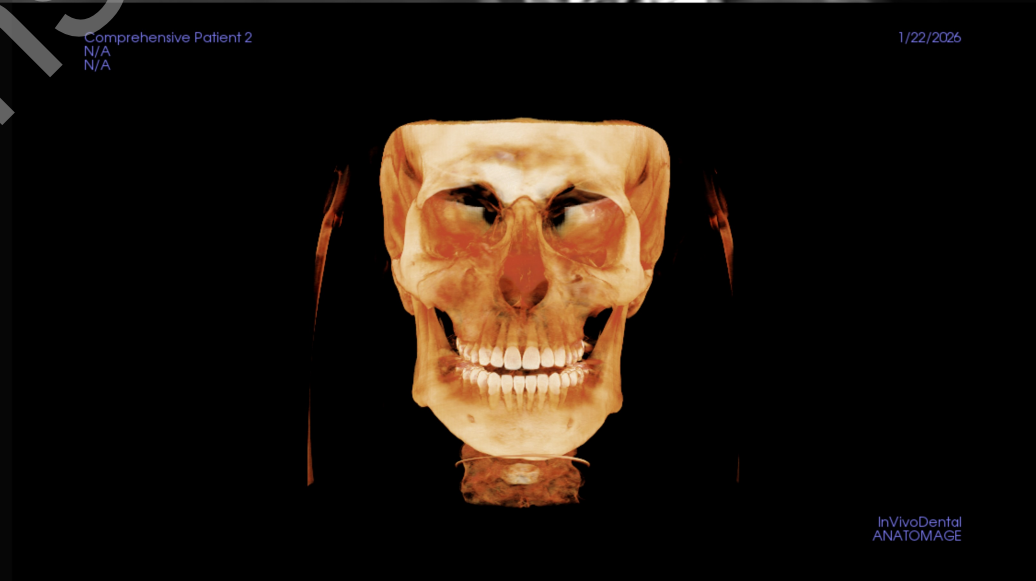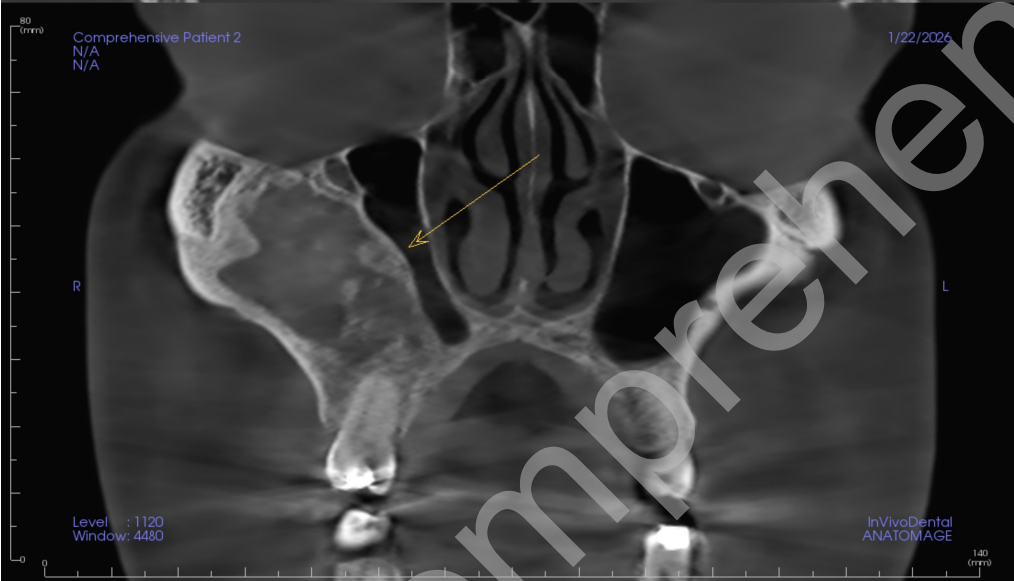
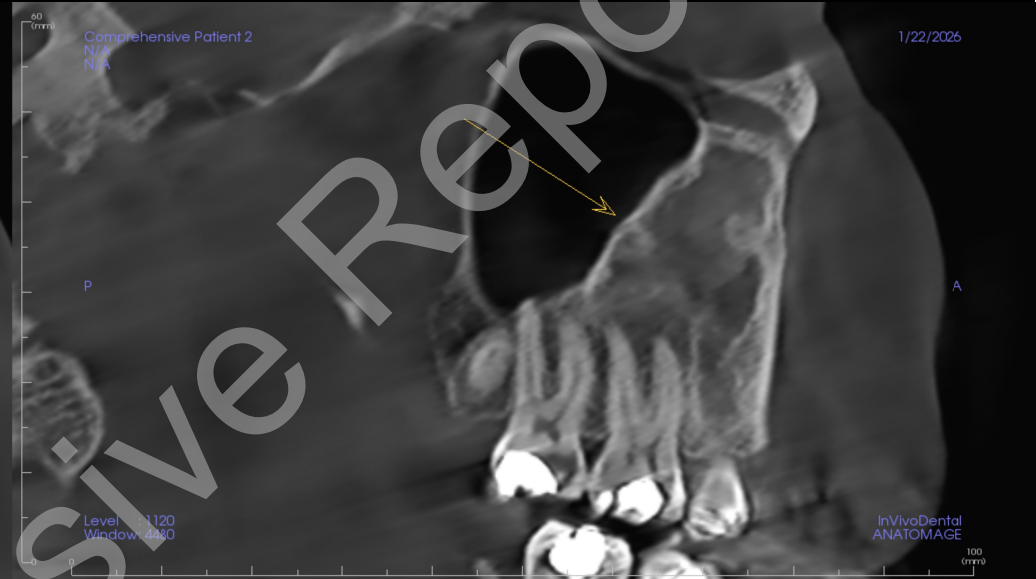
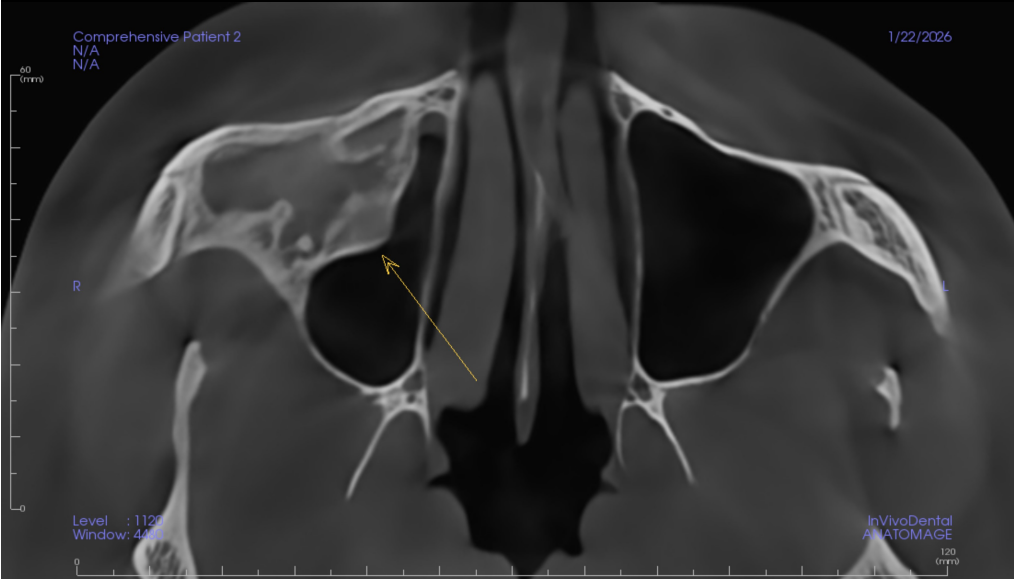
Preview



May Not Be Life Size

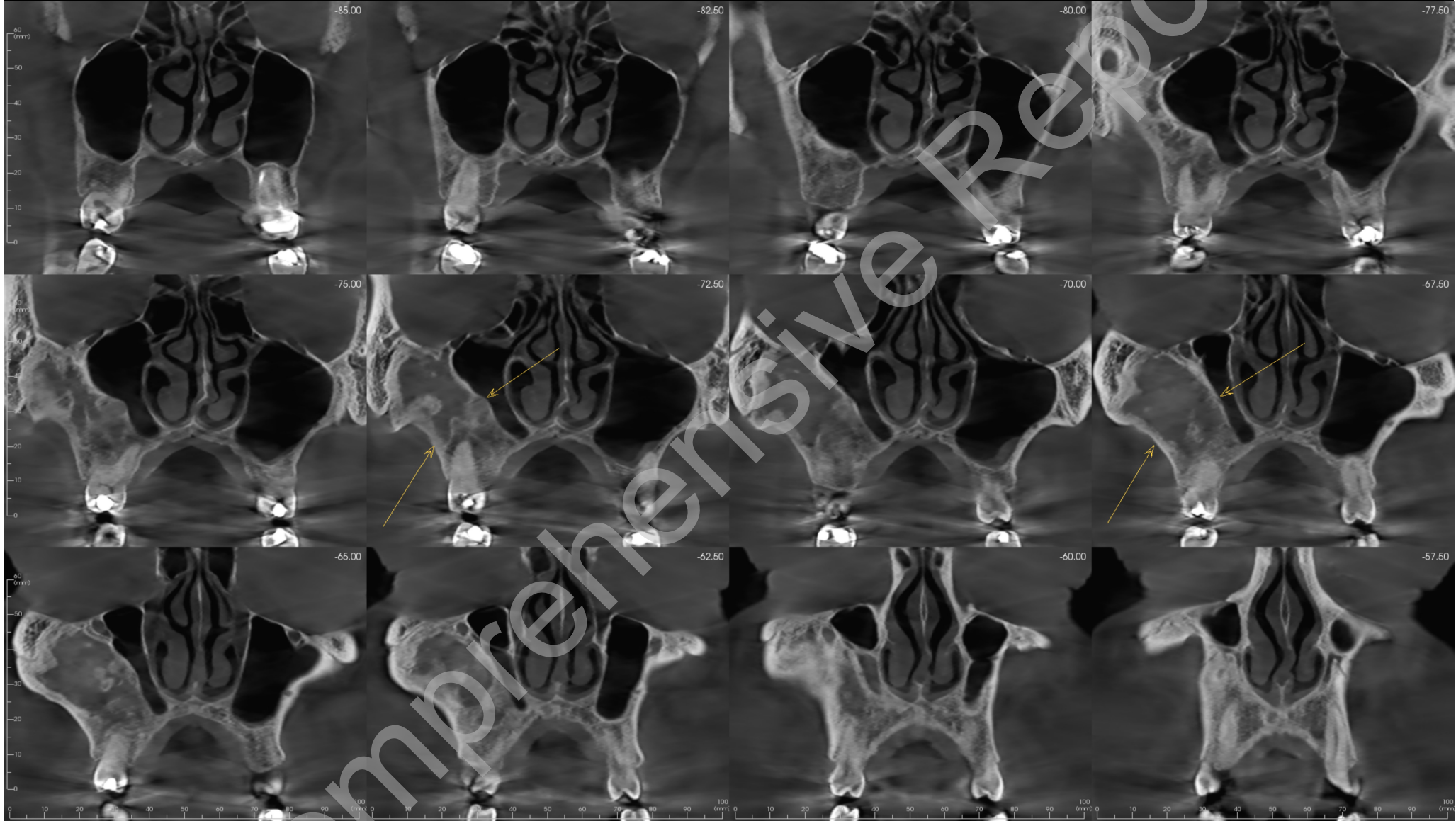
N/A

N/A



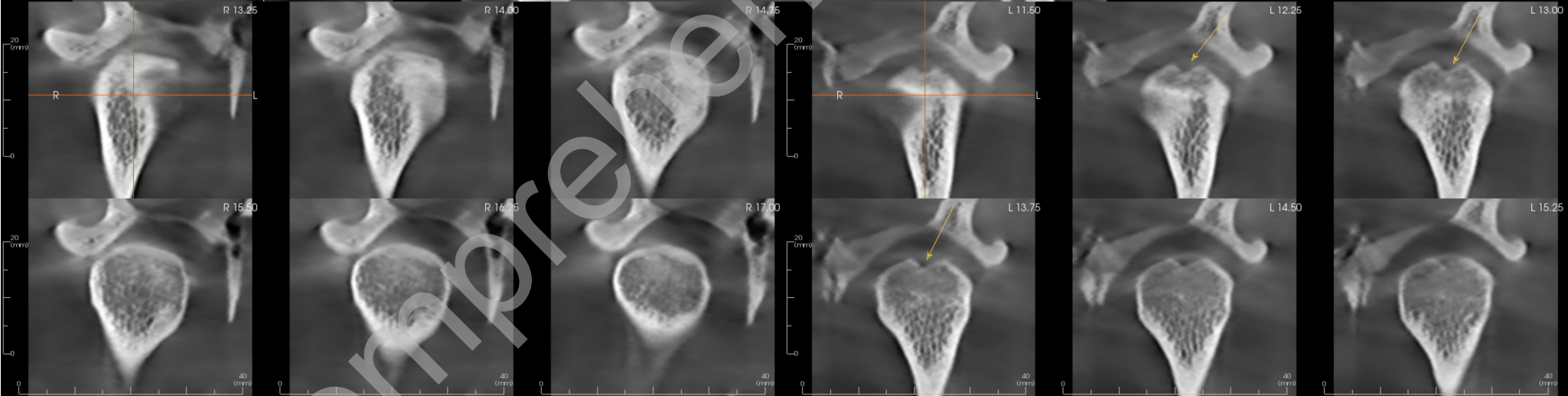
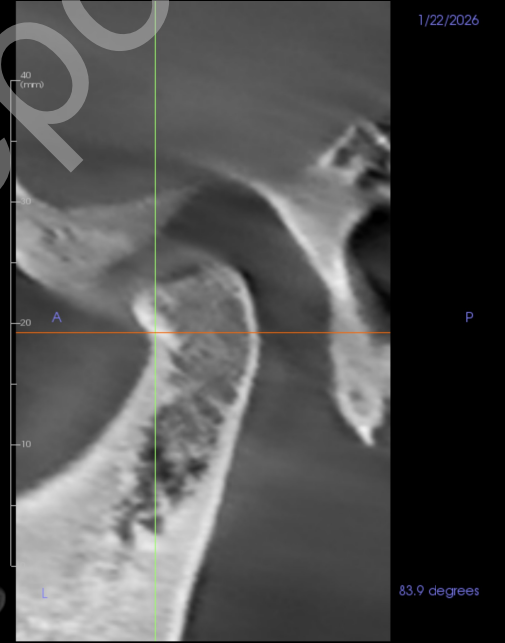
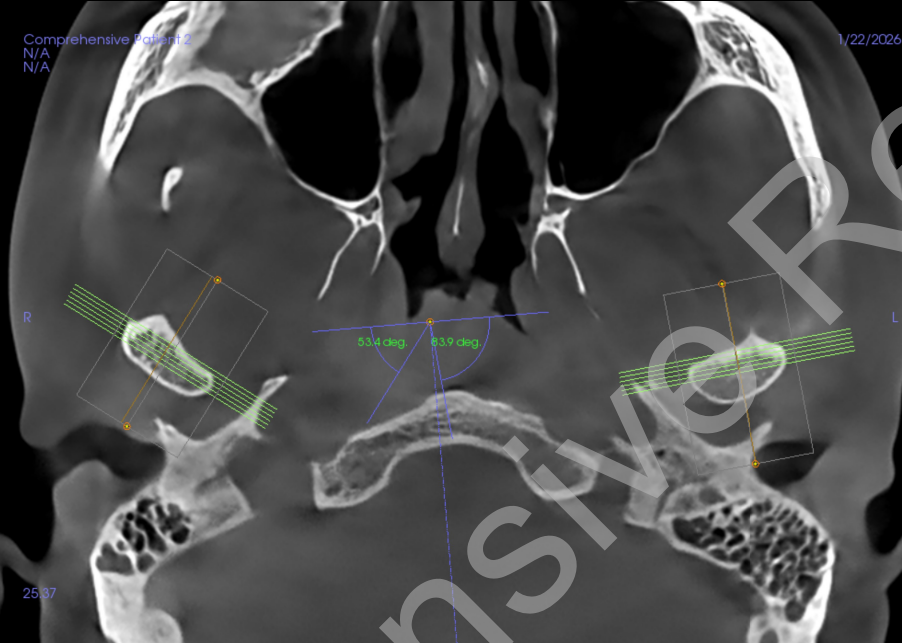
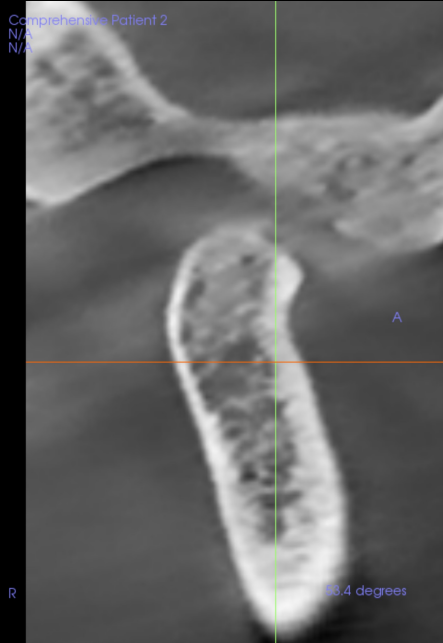
N/A

N/A



N/A

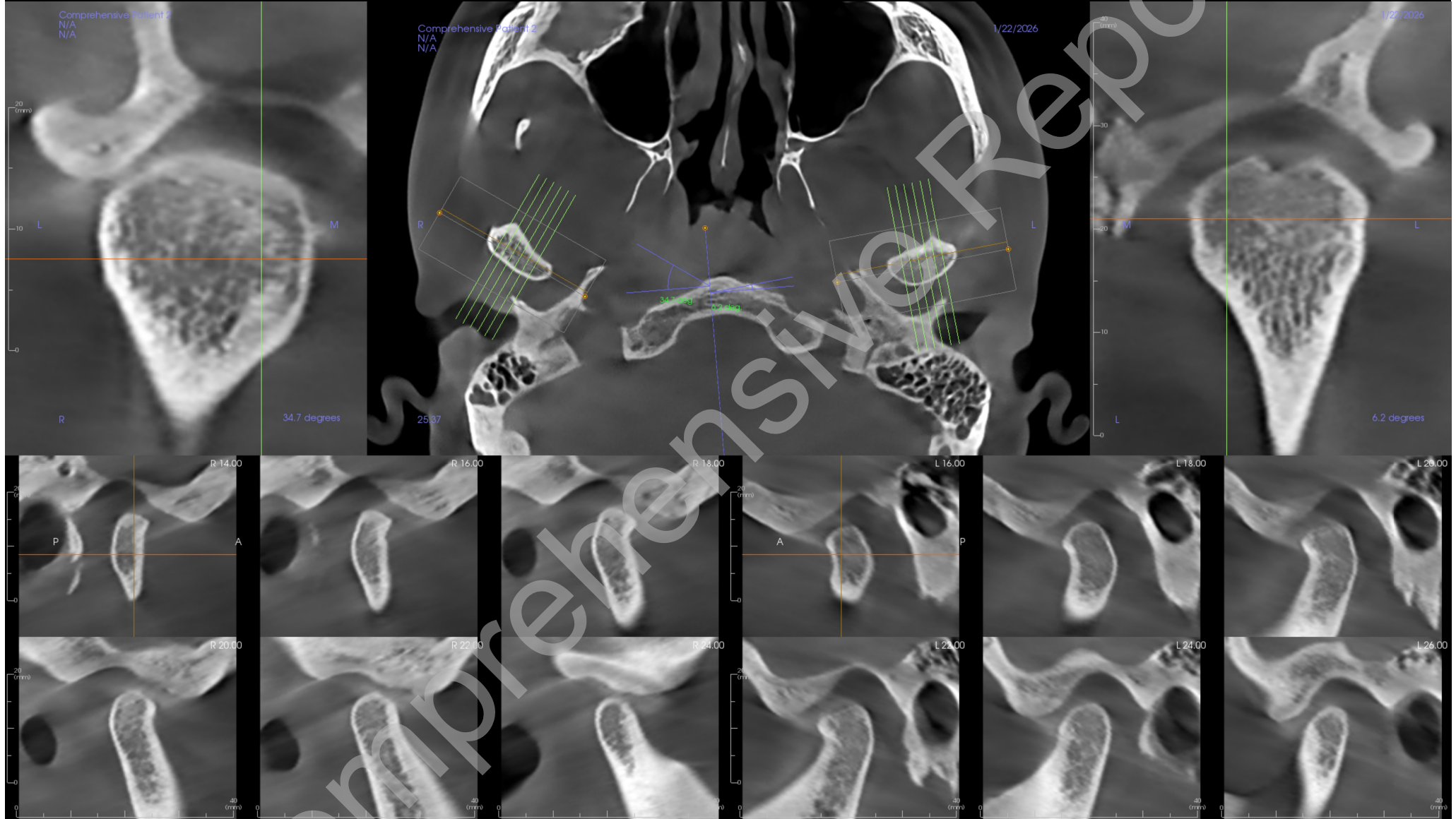
N/A



May Not Be Life Size

N/A

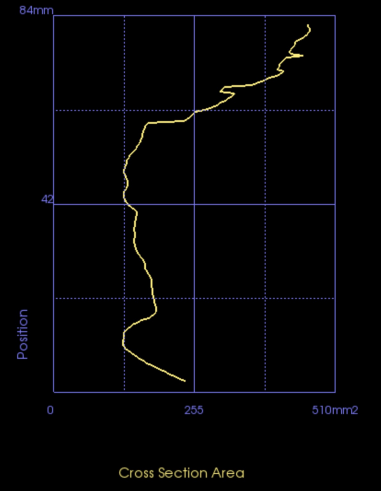
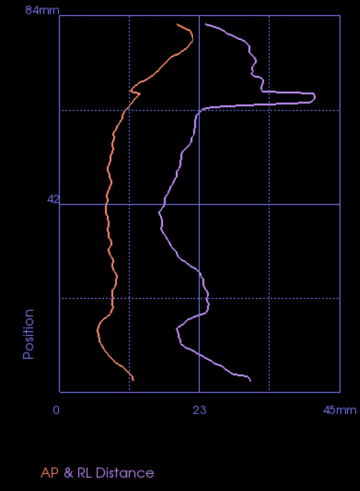
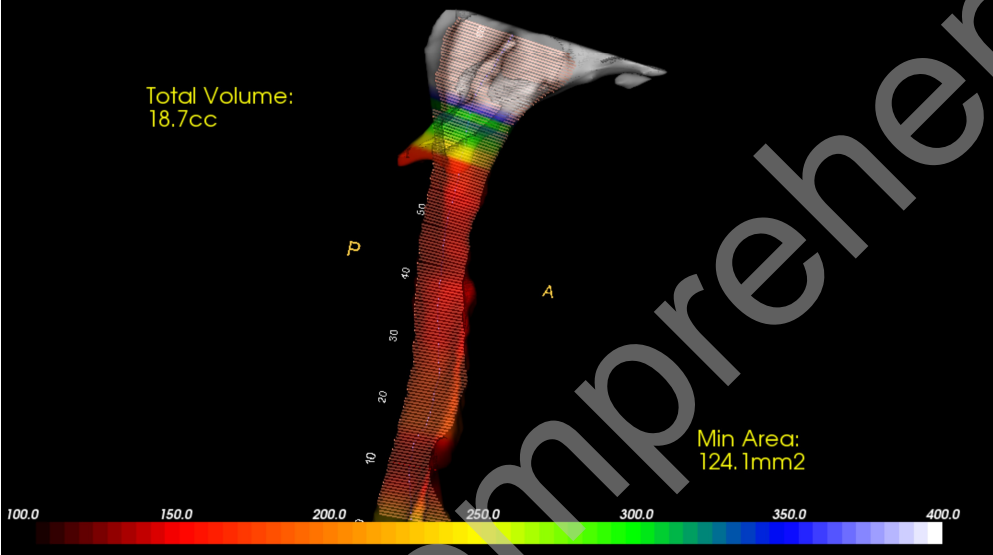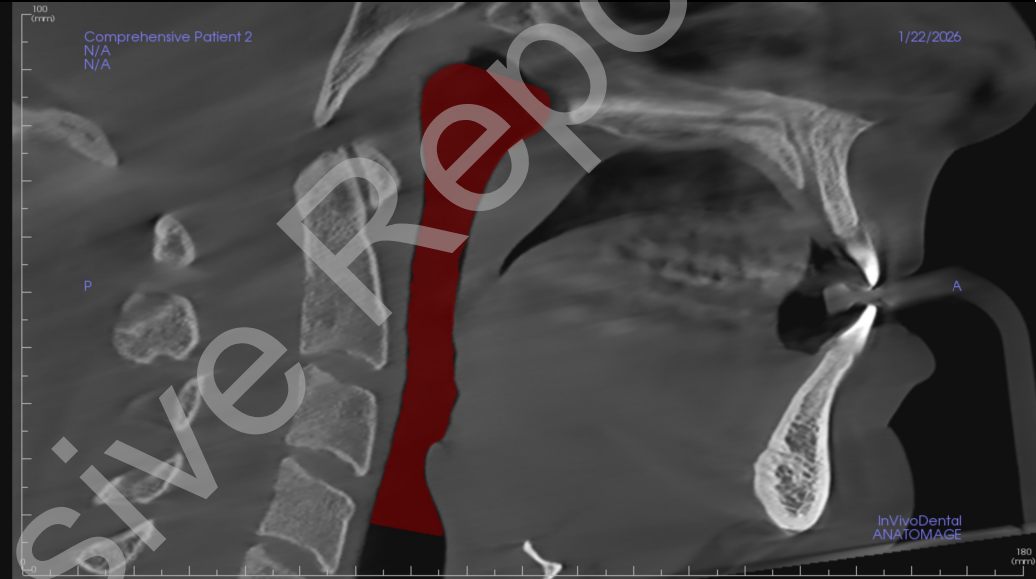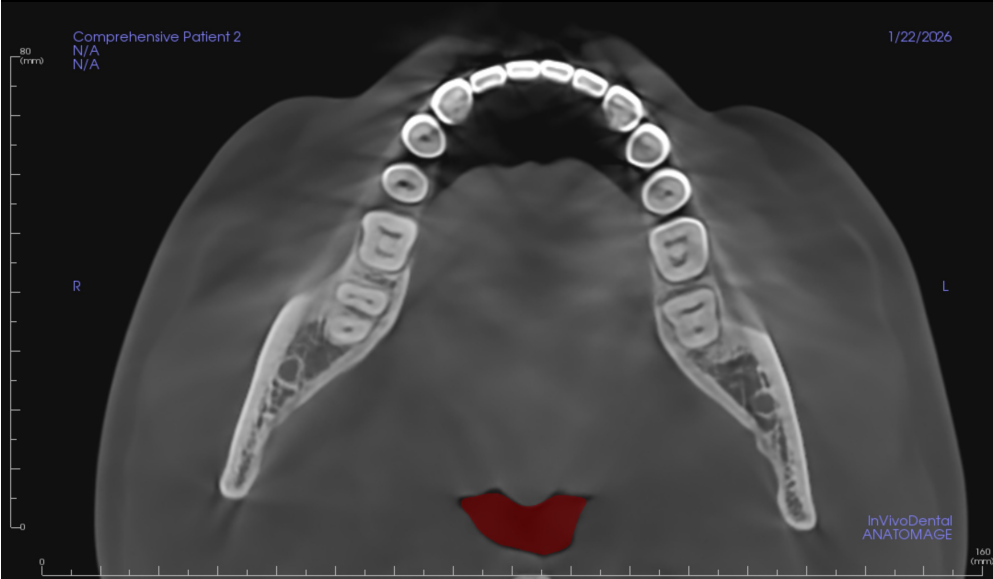
N/A



May Not Be Life Size

N/A

N/A



May Not Be Life Size

Pathology Screening

Example 2

Patient:

Date of Birth:

Referred By:

Case Information

Study Details

CBCT, both jaws with cranium

Scan Date

Image quality

Optimal for diagnosis

Clinical Indication

Pathology screening.

Radiographic Findings

Mixed density lesion, right maxilla:

There is a mixed radiopaque and radiolucent lesion involving the lateral right maxilla, extending from teeth #2–6 and reaching the floor of the orbit, with significant cortical expansion but no tooth displacement. The radiographic appearance is consistent with fibrous dysplasia, with no extension beyond the zygomaticomaxillary suture.

Dentition, Mandible, Maxilla:

The dentition and remaining paradental bone appear unremarkable with no sign of infection or pathosis.

TMJs:

There are features suggestive of bone remodeling of the left and right TMJs. Additionally, the left condylar head demonstrates a bifid morphology (a normal anatomical variation).

Sinuses, Nasal Cavity, Airway:

The visualized sinuses are clear and well aerated.

The nasal cavity demonstrates a patent air space and normal development.

The airway is patent with a relatively symmetric outline.

Other:

The remaining bones, soft tissues, and other structures captured in the scan have been evaluated and appear within normal limits.

Impressions

Mixed density lesion, right maxilla:

A mixed density lesion within the lateral anterior portion of the maxilla, consistent with fibrous dysplasia. Management is generally conservative, with clinical and radiographic follow-up recommended to monitor for any progressive growth. Surgical intervention is typically only considered when there is functional impairment, cosmetic concerns, or significant progressive growth. Biopsy is only indicated when significant growth is exhibited.